

BRAIN AND CRANIAL NERVES LAB VIDEO RECORDING LINK AND TERMINOLOGY LIST

Dr. Lisa Brinn

Video Recording Link for Lab

- [Module 11 Lab Exercise 23 Specialized dura mater](#)
- [Module 11 Lab Exercise 23 Ventricles](#)
- [Module 11 Lab Exercise 23 Brain Regions](#)
- [Module 11 Lab Exercise 23 Brain and Ventricles](#)
- [Module 11 Lab Exercise 24 Cranial Nerves](#)

Video Recording Link for Lecture Content

- [Module 11 ML01 Video Brain Functions and Structures](#)
- [Module 11 ML02 Video Diencephalon and Cerebellum](#)
- [Module 11 ML03 Video Cerebrum and Limbic System](#)
- [Module 11 ML04 Video Cranial Nerves](#)

Terminology List

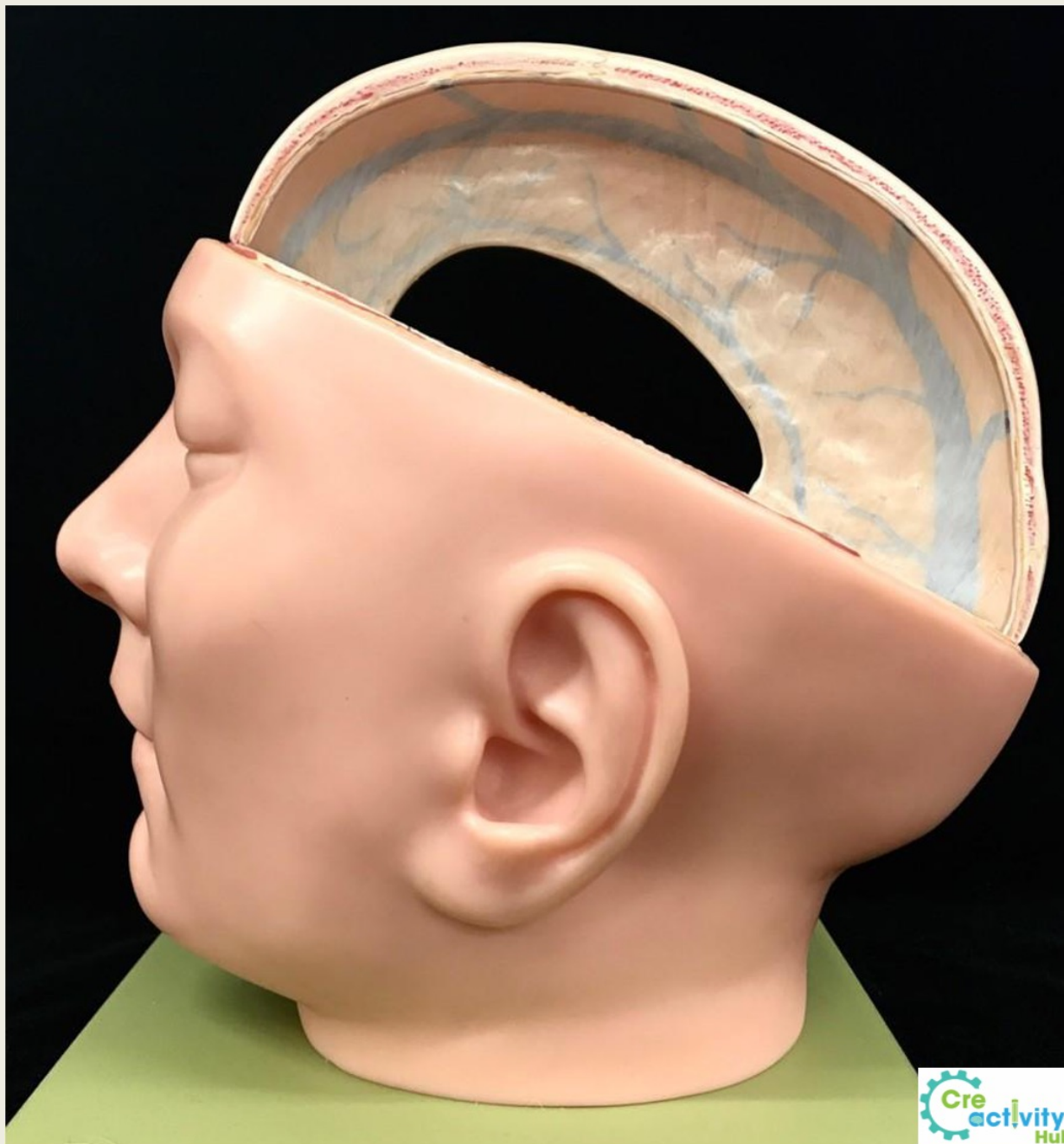Lobes	Sulci	Cortex Areas
<ul style="list-style-type: none">● frontal lobe● temporal lobes● occipital lobe● parietal lobes	<ul style="list-style-type: none">● central sulcus● lateral sulcus● parieto occipital sulcus	<ul style="list-style-type: none">● motor cortex● sensory cortex● visual cortex● auditory cortex

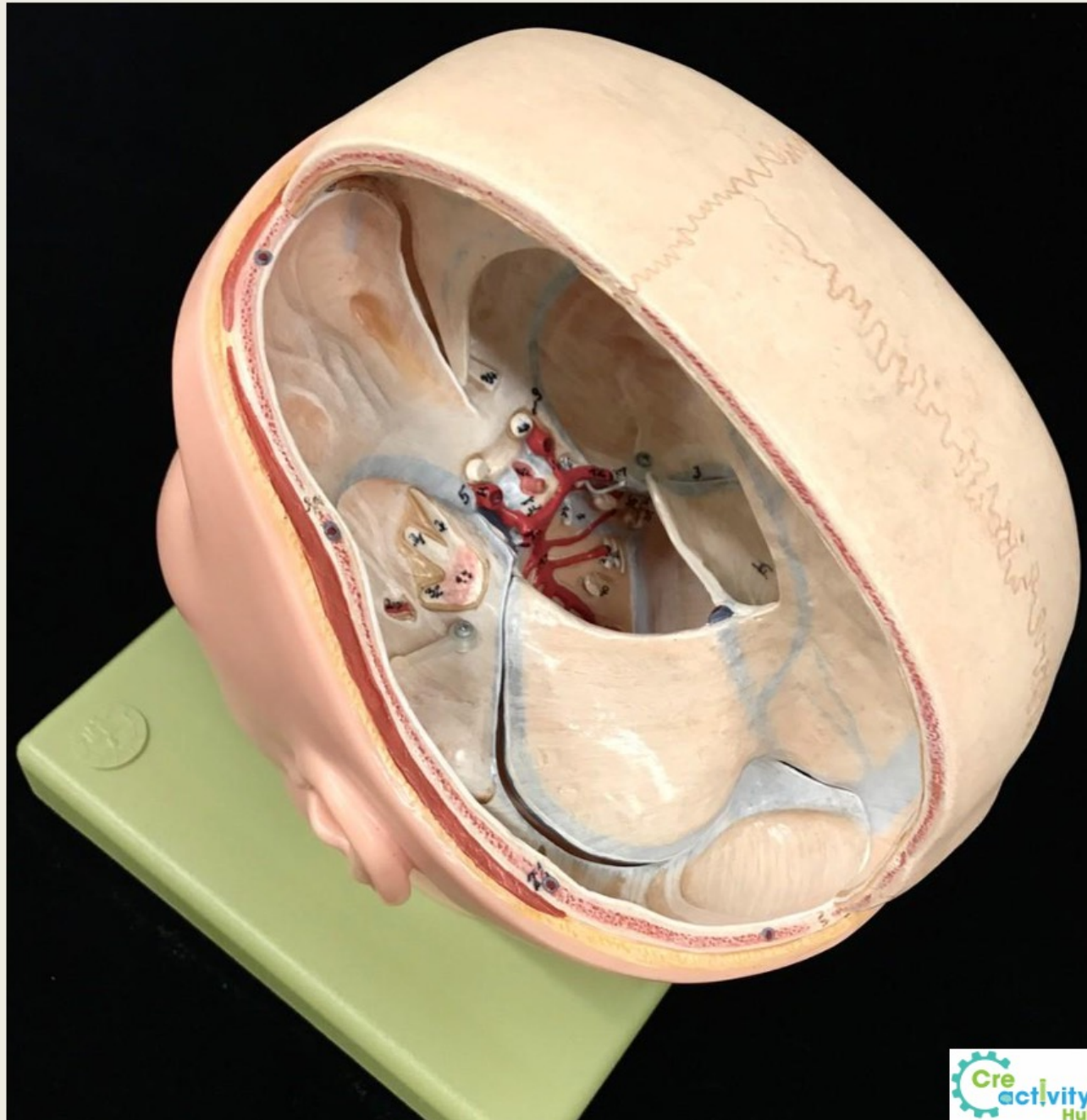
Terminology List

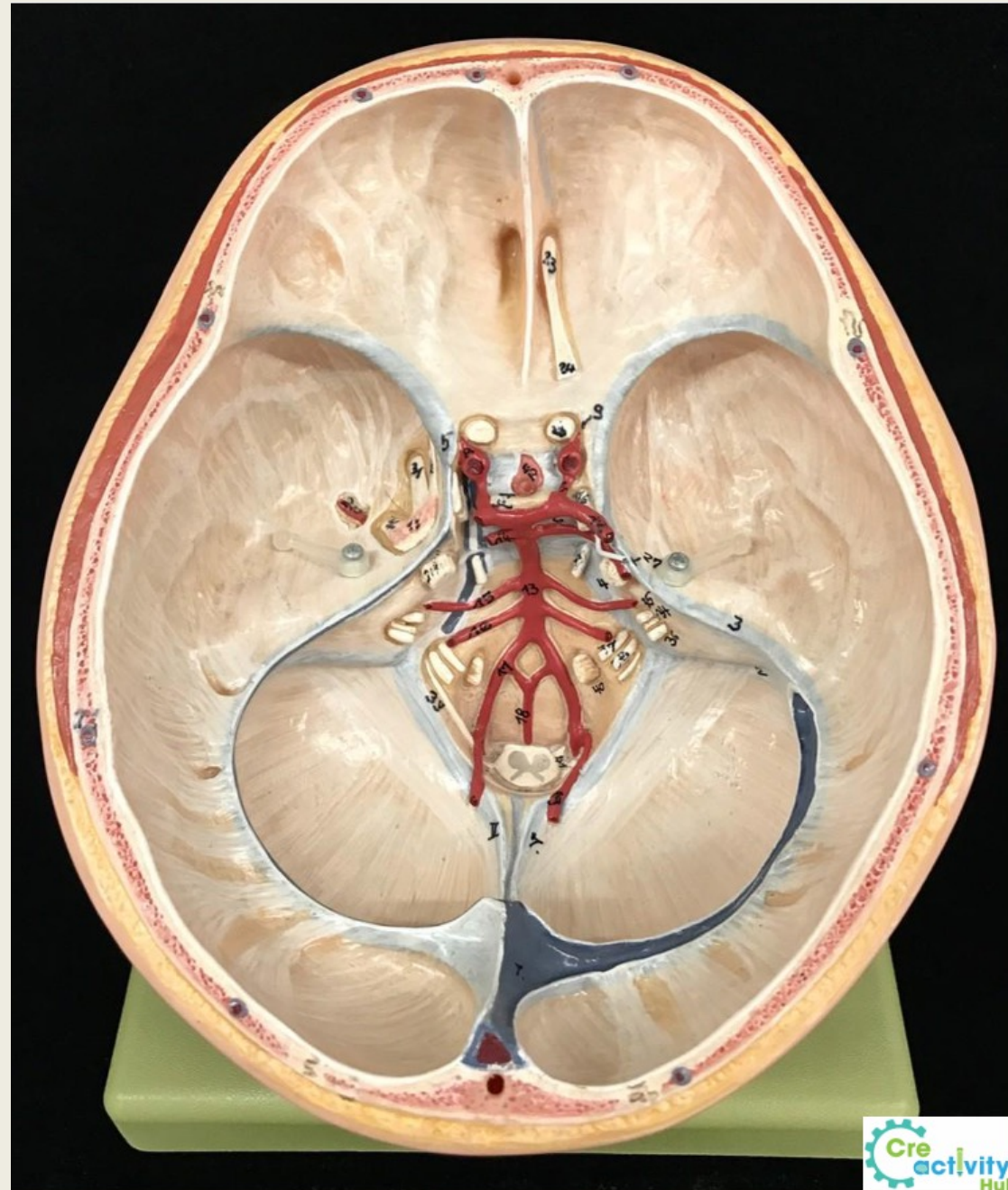
Brain Structures	Ventricles
<ul style="list-style-type: none">• cerebrum• corpus callosum• fornix• epithalamus• thalamus<ul style="list-style-type: none">➤ interthalamic adhesion• cerebellum• pons• medulla oblongata• spinal cord	<ul style="list-style-type: none">● lateral ventricles● septum pellucidum● interventricular foramen● third ventricle● aqueduct of midbrain● fourth ventricle● choroid plexus

Terminology List

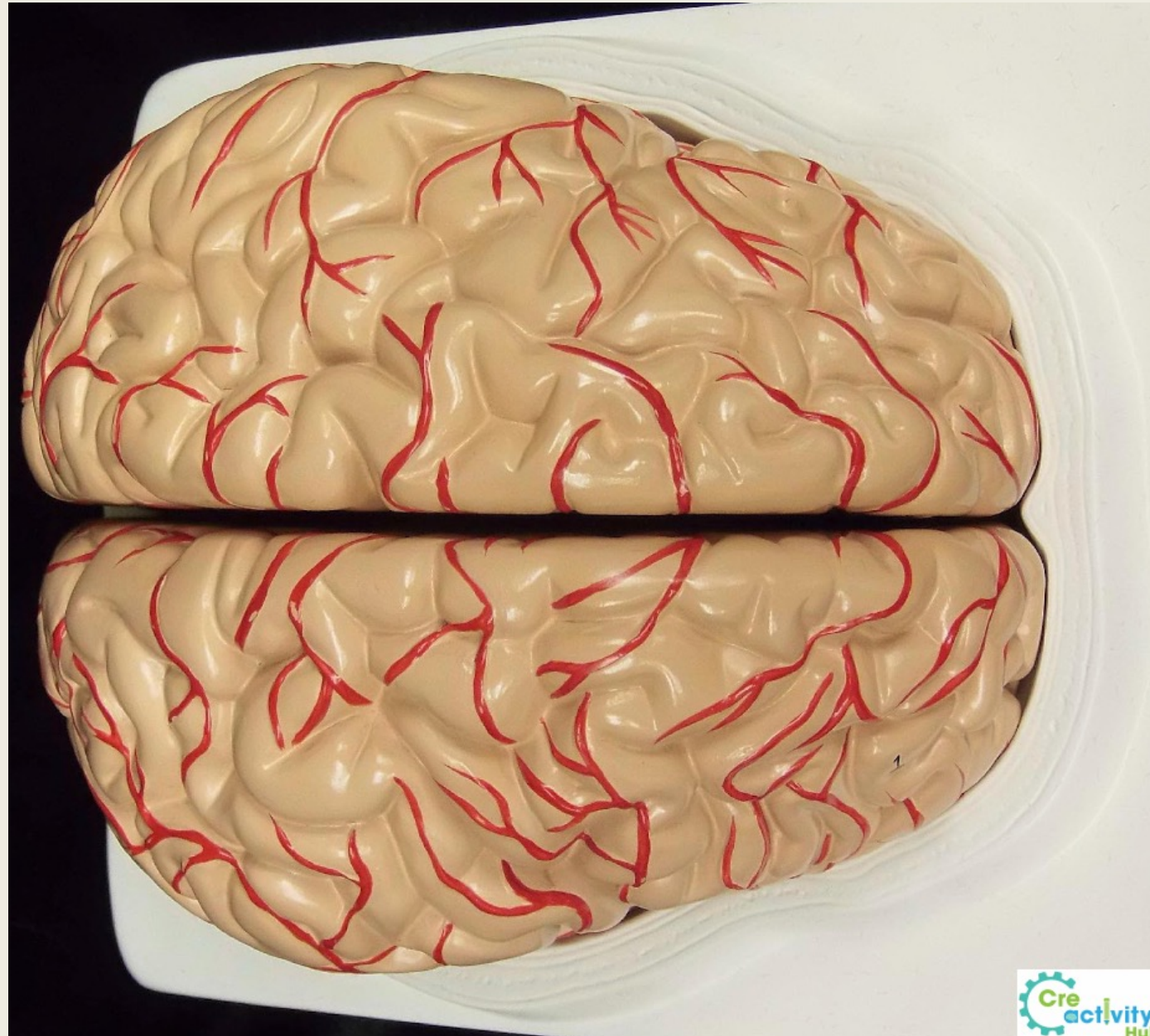
Sinuses	Dura Mater Structures
<ul style="list-style-type: none">● transverse sinus● superior sagittal sinus● inferior sagittal sinus● straight sinus	<ul style="list-style-type: none">● falx cerebri● falx cerebelli● tentorium cerebelli● diaphragma sellae



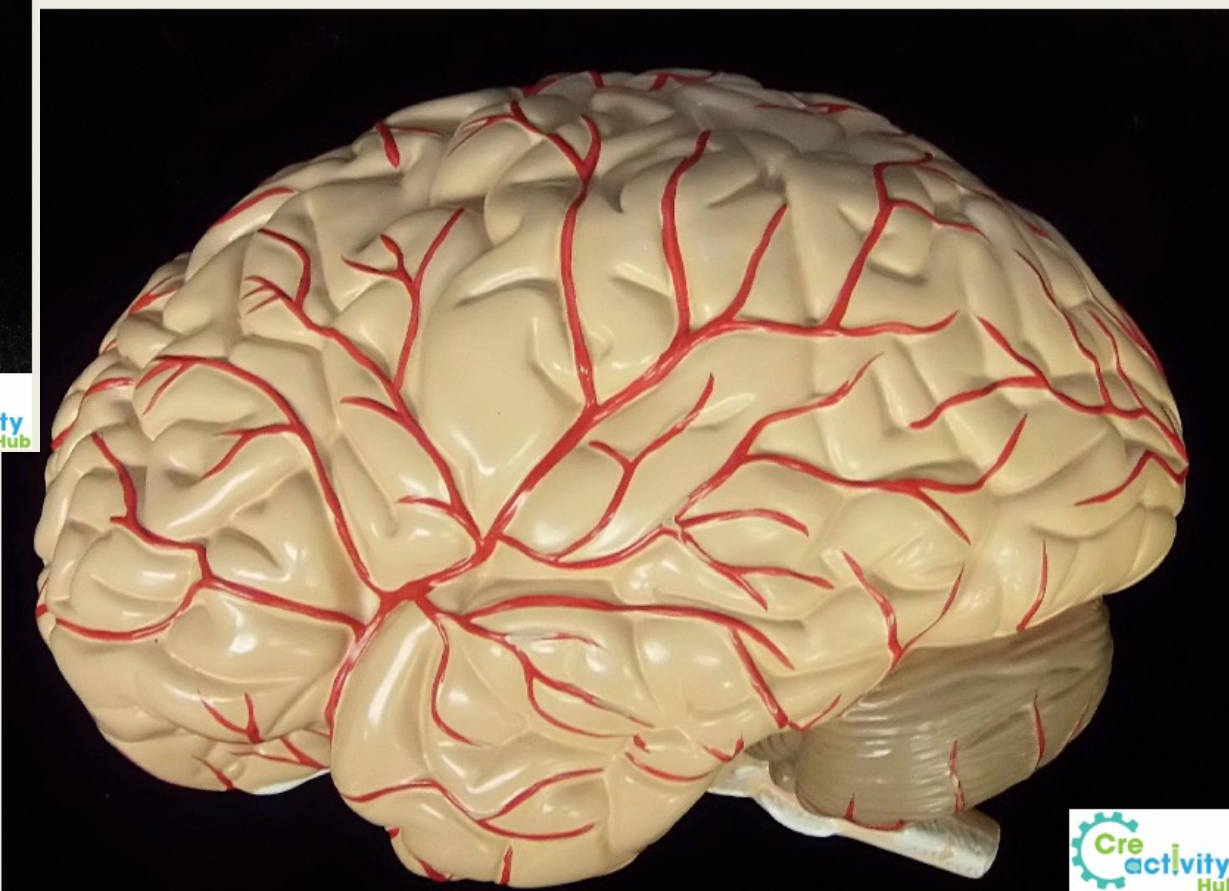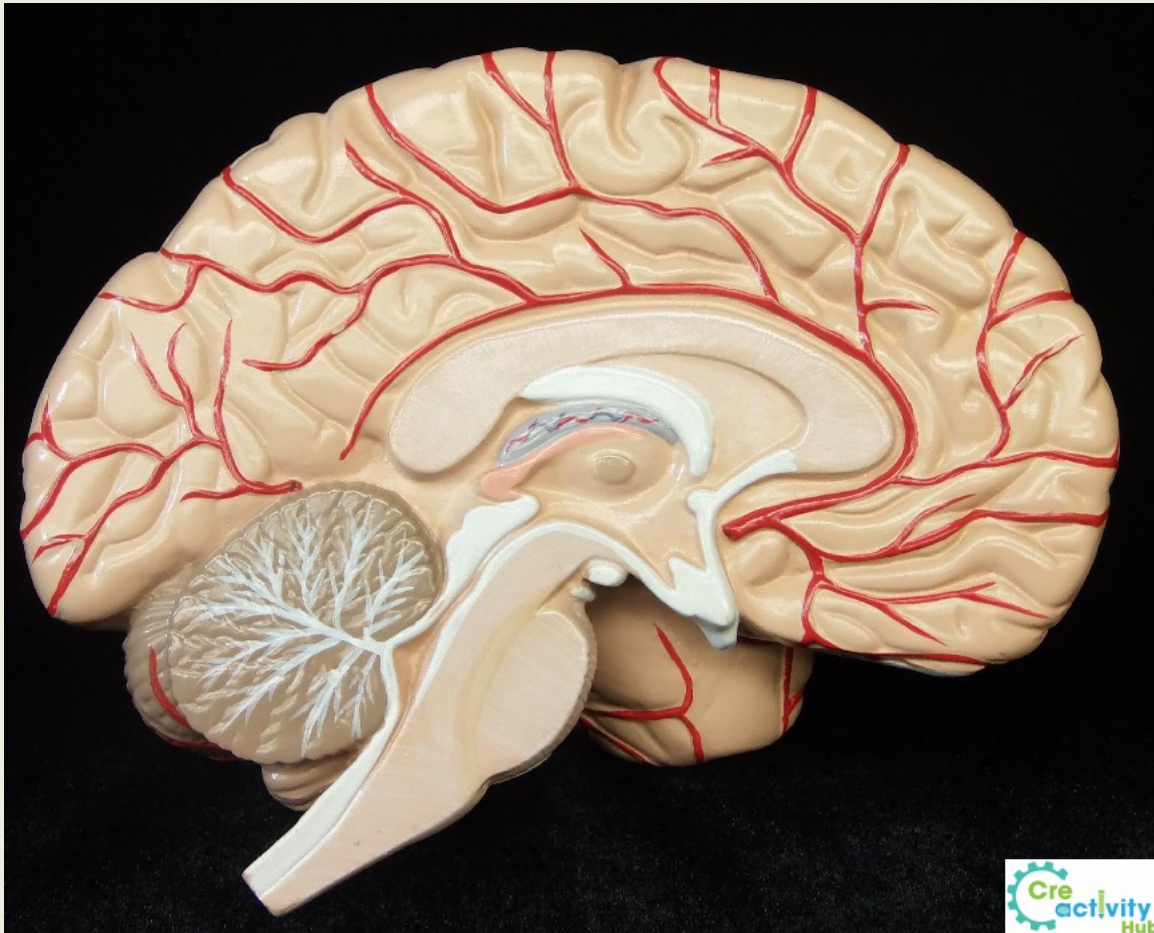


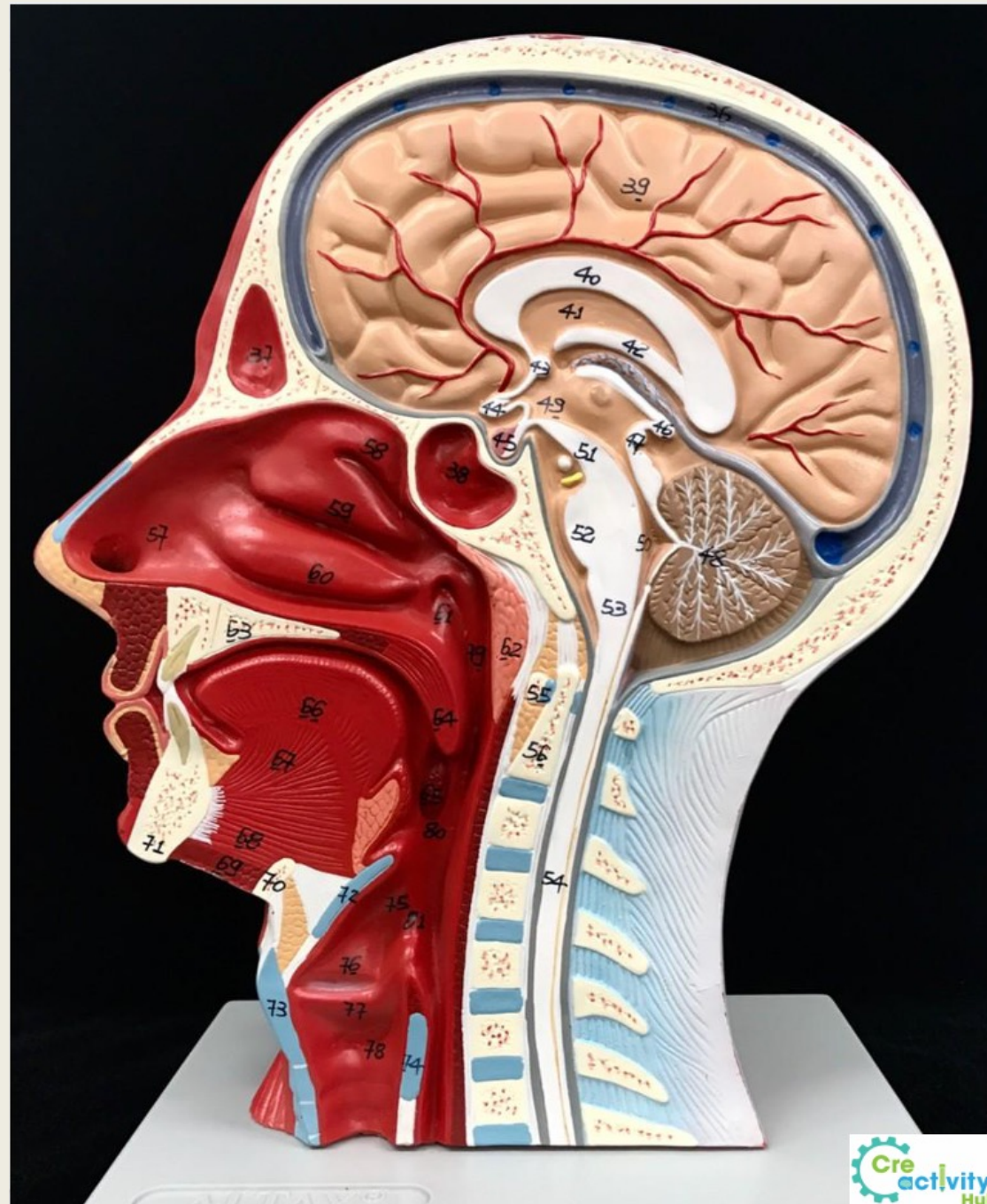


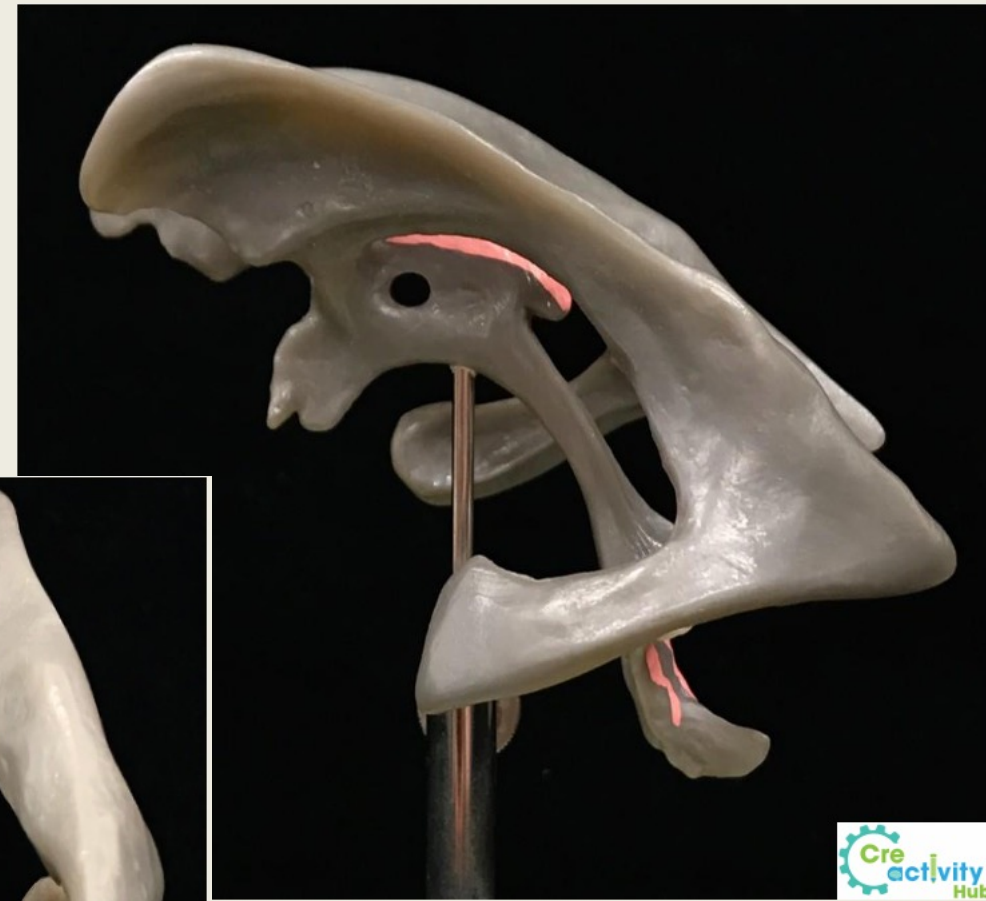
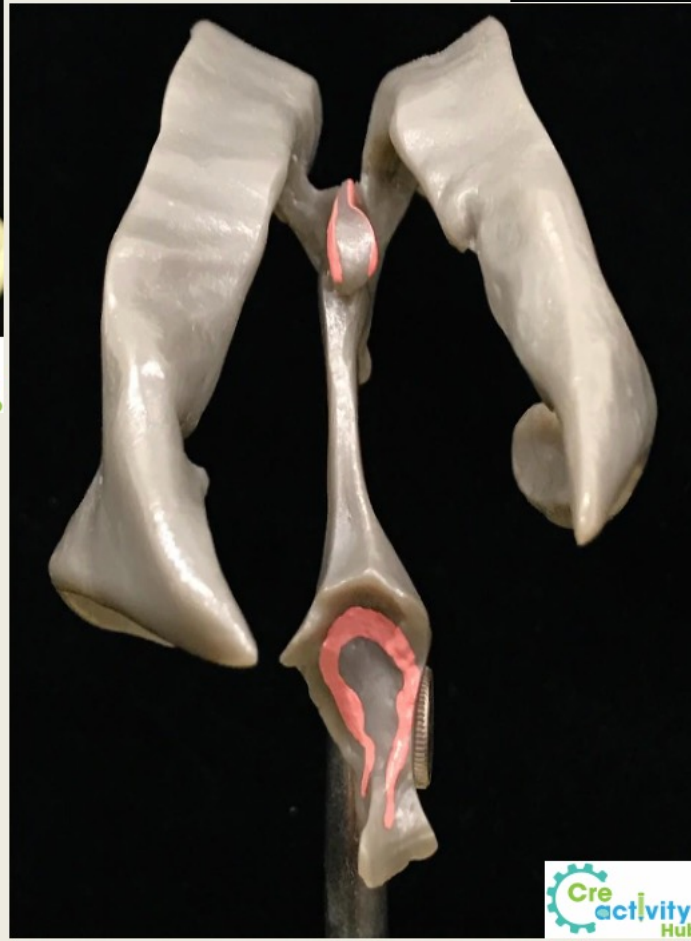Posterior



Anterior







Terminology List

Cranial Nerves	Cranial Nerves Pneumonic	Cranial Nerves Functions
CN I – olfactory nerve	Oh	Some
CN II – optic nerve	Once	Say
optic chiasm	One	Money
CN III – oculomotor nerve	Takes	Matters
CN IV – trochlear nerve	The	But
CN V – trigeminal nerve	Anatomy	My
• ophthalmic branch	Final	Brother
• maxillary branch	Very	Says
• mandibular branch	Good	Big
CN VI – abducens nerve	Vacations	Brains
CN VII – facial nerve	Are	Matter
CN VIII – vestibulocochlear nerve	Heavenly!	Most
CN IX – glossopharyngeal nerve		Where:
CN X – vagus nerve		S = sensory
CN XI – accessory nerve		M = motor
CN XII – hypoglossal nerve		B = both

